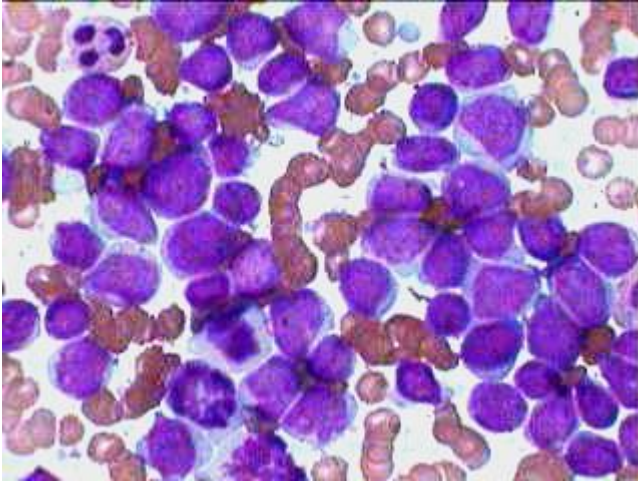




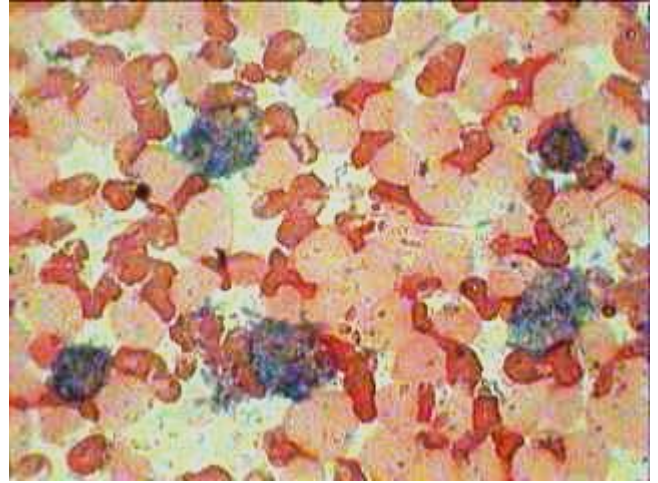
Estd. 1999

www.pathoindia.com

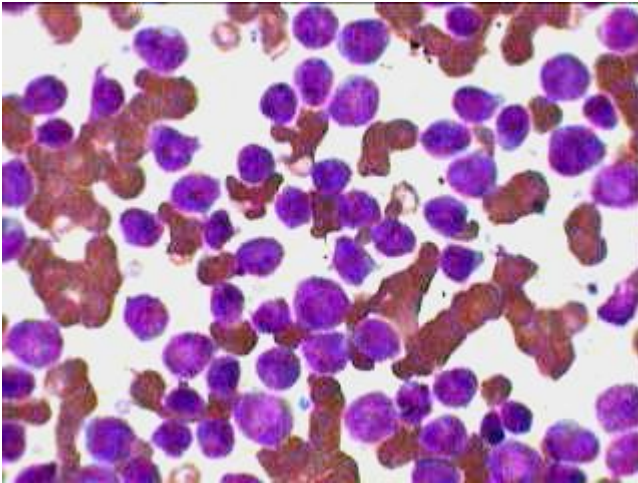
One patient showing Myeloblastic while the other showing Lymphoblastic Crisis in CML



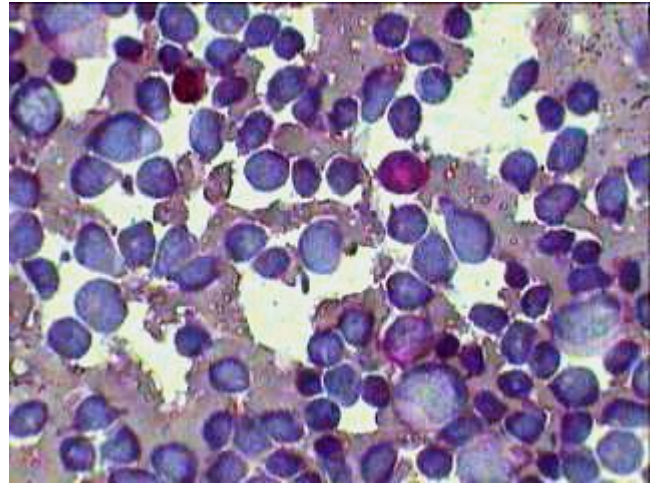
Ac. Myeloblastic Crisis in CML simulating AML. But this (58 years) case returned after about a year of discontinuing the chemotherapy for CML.



Same patient as on left with MPO stain showing peroxidase negative blasts and few positive more mature myeloid cells.



Another patient (16 yrs) of old CML came with Acute Lymphoblastic crisis, morphologically all the blast cells resemble Lymphoid blasts.



Same patient as on the left with PAS stain showing few diffuse PAS positive more mature myeloid cells but negative lymphoid blast cells.