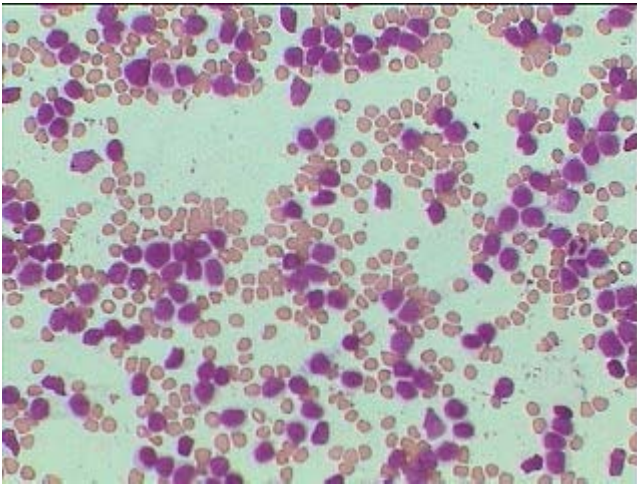
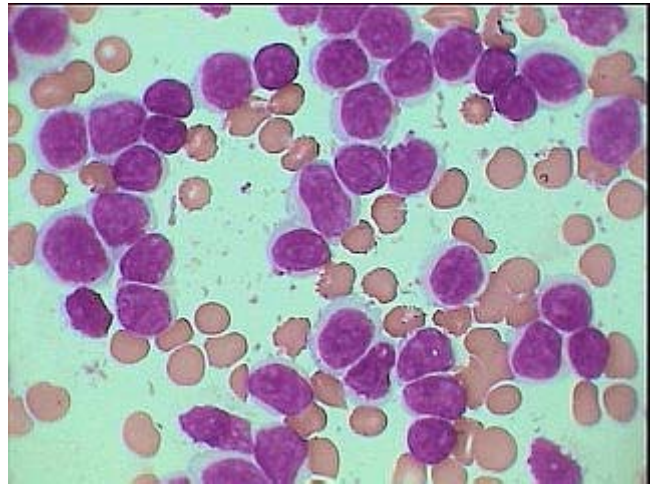


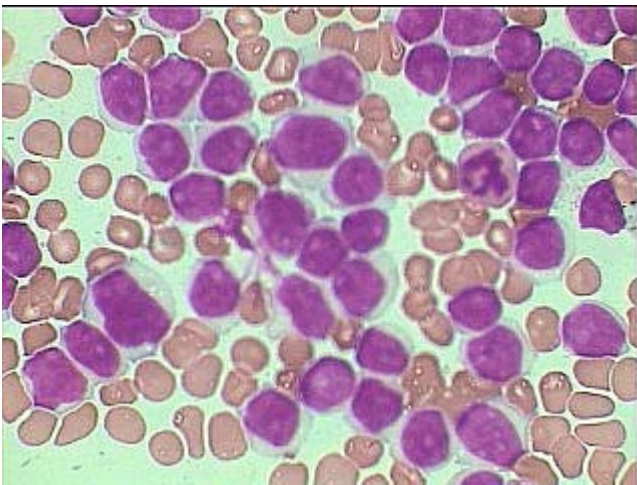
Prolymphocytic Leukemia (de novo)
& it is not typical CLL transforming to PLL



Prolymphocytes packing almost entire field under HP, from a case of Prolymphocytic leukemia. Better appreciable images under Oil Imm.



Prolymphocytes –relatively large lymphoid cells showing fine but dense nuclear chromatin pattern with distinct to indistinct single nucleoli, under Oil Imm.



Pleomorphic large lymphoid cells showing relatively large variable amount of light basophilic cytoplasm and distinct single nucleoli in most of the cells- a case of Prolymphocytic leukemia.