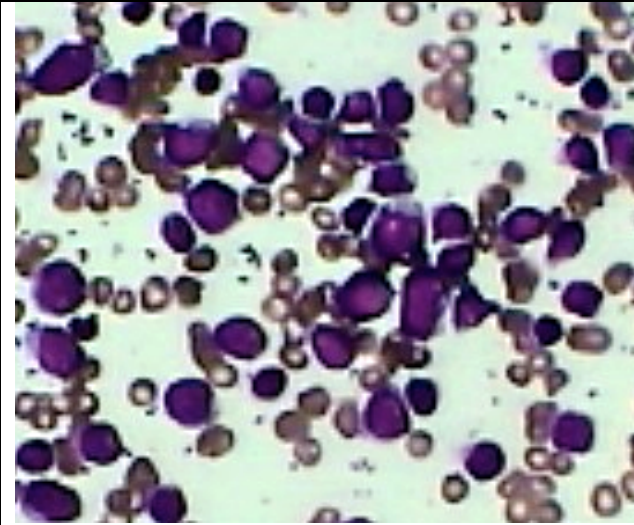
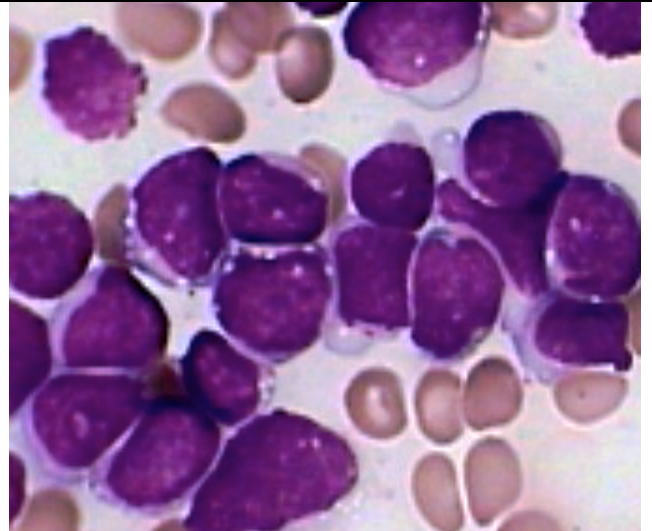


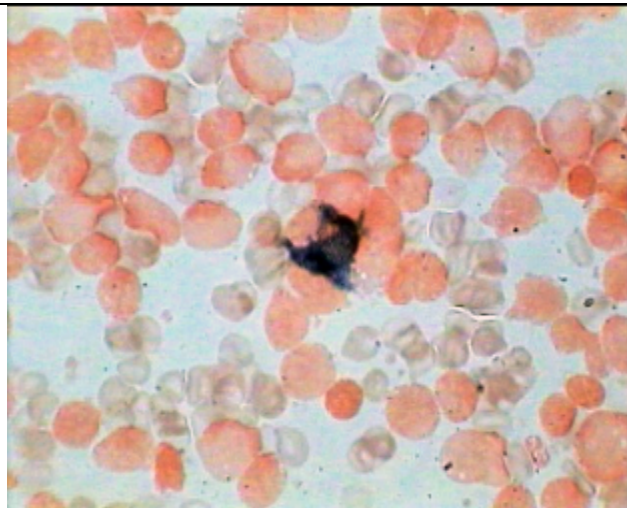
Acute Leukemia Type L-3 (Burkitts Type)



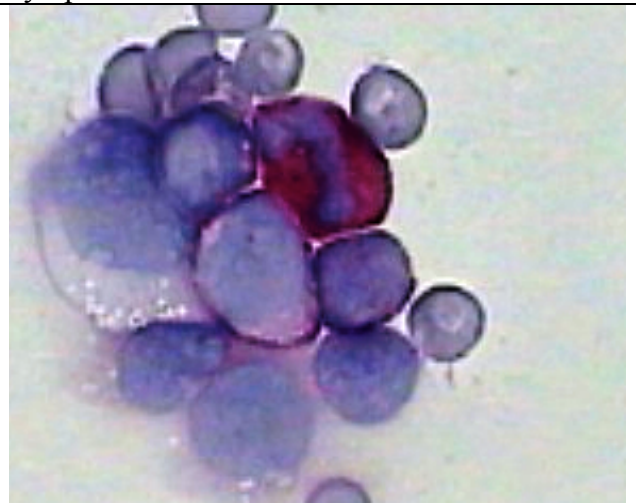
Medium size Immature Leucoblasts with Scanty basophilic Nongranular cytoplasm



Same as on the left in higher magnification showing dense nuclear chromatin, distinct cytoplasmic/nuclear vacuolization Burkitts cells



MPO stain with safranin counterstain showing all Burkitts cells negative for peroxidase and only one Mature myeloid cells in the center showing peroxidase positivity



PAS stain in higher magnification showing One diffuse staining of the mature myeloid cell and two adjoining Lymphoid cells (Burkitts type) have Dot PAS positive granules. One Unusually large cells showing Cytoplasmic vacuolization