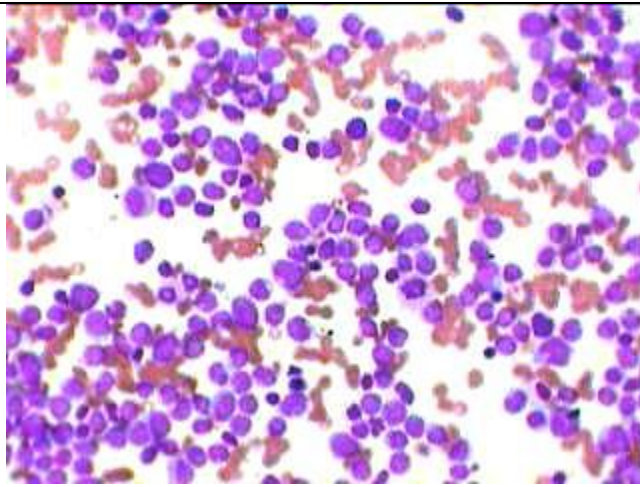
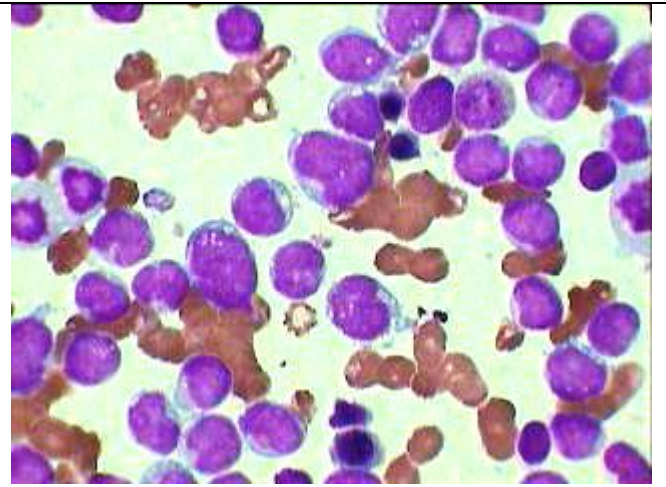


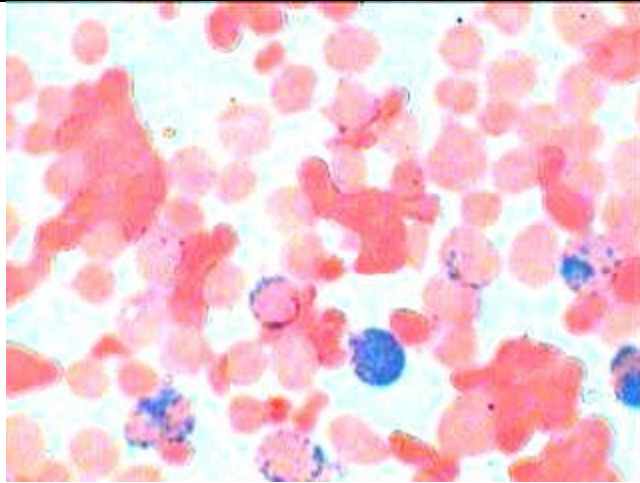
Acute Leukemia MPO + With Vacuolar Degeneration



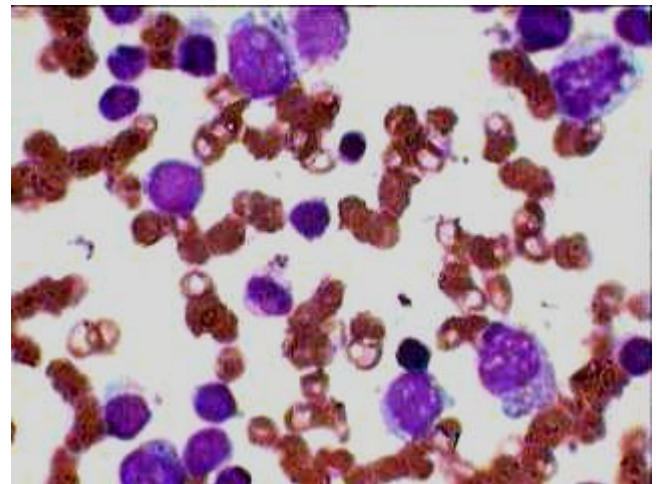
Almost all the cells are neoplastic leucoblasts as seen under HP in Marrow aspiration smear



Oil imm view of the same showing intra-nuclear vacuoles in some of the blast cells.



Peroxidase positivity in 5 of the blast cells (myeloid blasts) besides 2 more mature myeloid cells



Very distinct nuclear vacuolization besides more than two nucleoli as seen in three myeloid blasts. Differentiate between nucleoli & Vacuoles.