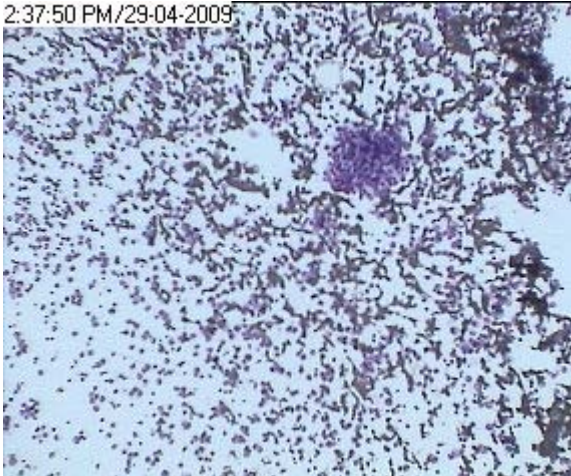

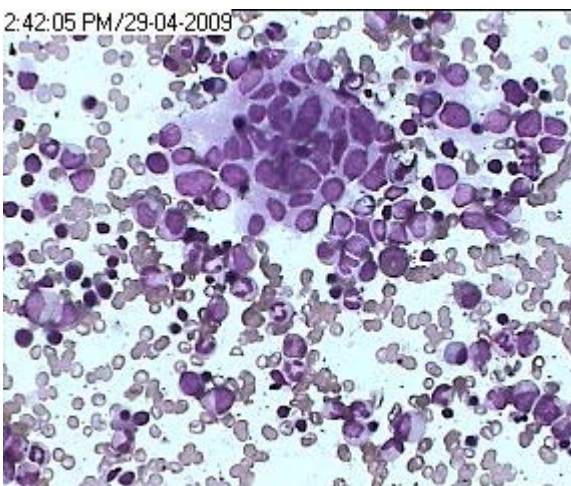
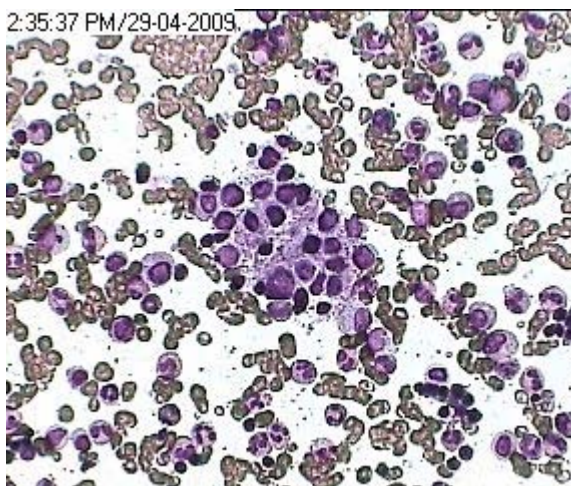


Neuroblastoma-Metastasis- in BM aspiration smear

 <p>2:37:50 PM/29-04-2009</p>	 <p>2:39:51 PM/29-04-2009</p>
<p>Low power view of BM Biopsy Imprint smear showing focal collection of metastasis.</p>	<p>Group of Neuroblastoma metastatic cells along with other normal Haemopoetic cells in BM smear of a child of 7 years age.</p>
 <p>2:42:05 PM/29-04-2009</p>	 <p>2:35:37 PM/29-04-2009</p>
<p>Focal collection of round to oval pleomorphic Neuroblastoma cells as tumor emboli, in BM smear showing almost normal Haemtopoesis.</p>	<p>Hypocellular Marrow in aspiration smear showing focal collection of Neuroblastoma cells. The rosette formation with central necrosis as observed in primary is absent in Mats here.</p>

This child had raised urinary catecholamine (VMA) excretion.