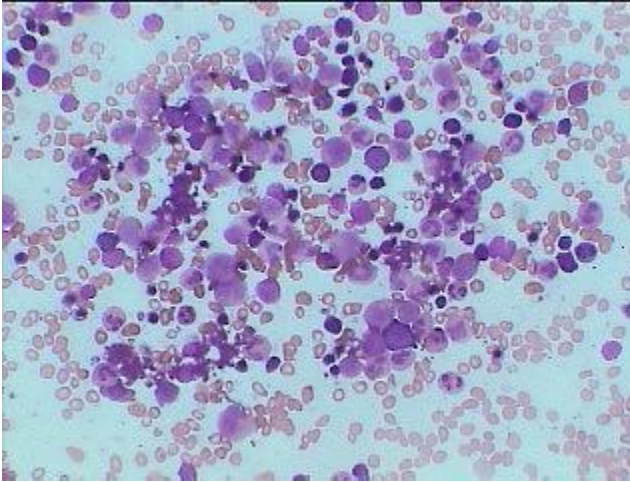
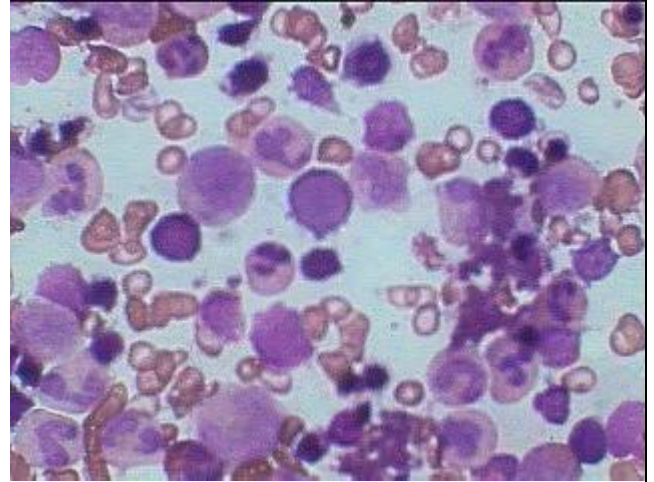




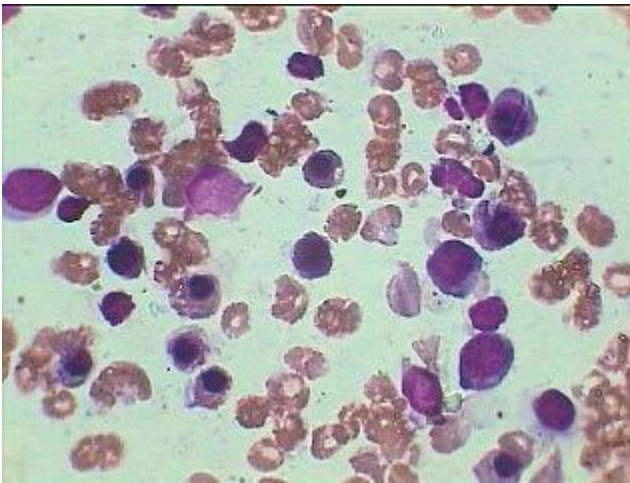
## Normal Bone marrow



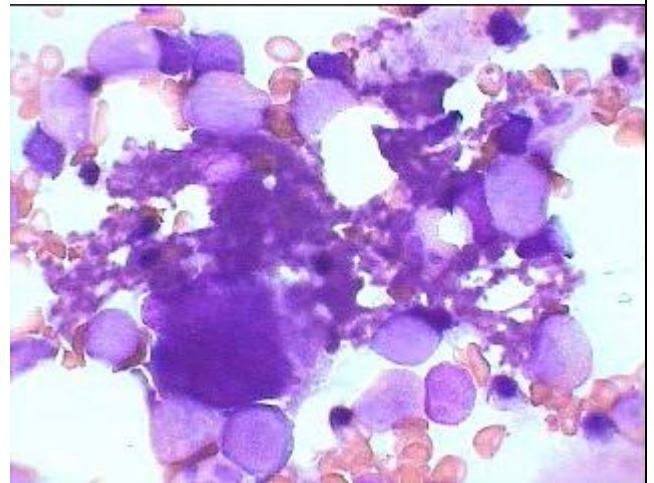
Normal Bone marrow under HP (Giemsa stain), showing normal Hematopoiesis.



Normal Bone.Marrow under oil immersion showing predominantly normal Granulopoiesis



Normal marrow showing predominantly normoblastic erythropoiesis



Normal B.Marrow showing Megakaryocytes having normal thrombopoiesis