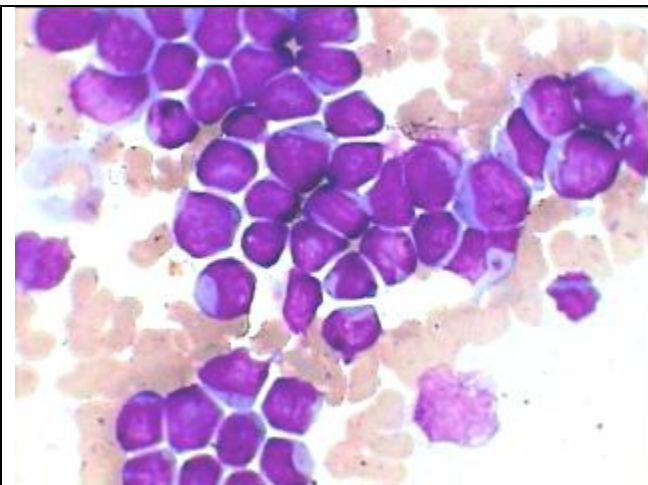
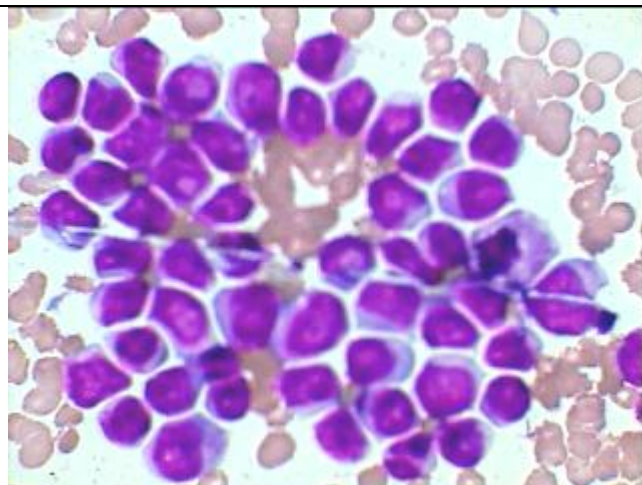


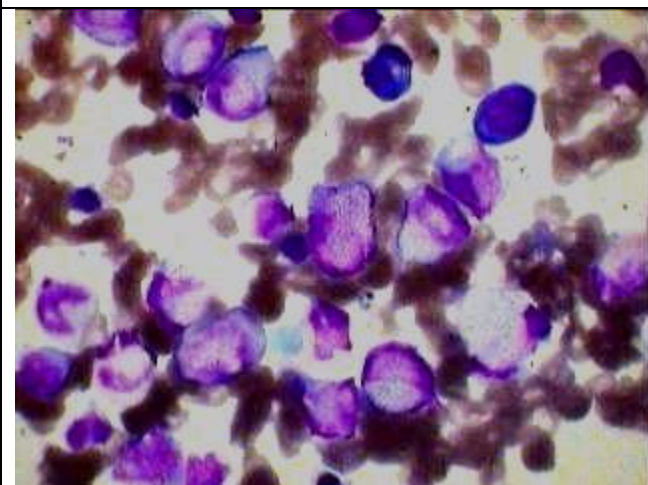
**AML- M-3 Hypogranular to Nongranular type-earlier confused to be M-1**



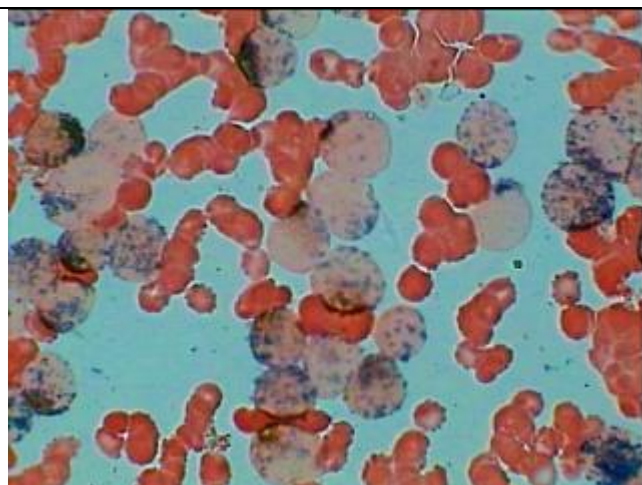
All the blast cells show basophilic Non-granular cytoplasm and there is complete absence of more mature myeloid cells-appearing as M-1



Same as that on the left in another field of the BM aspiration smear showing all the blast being nongranular.



Another smear of the same elderly patient showing one hypogranular promyelocyte in the center while the rest are nongranular along with two plasma cells.



Strong peroxidase positivity of the same patient-BM smear conclusively indicating it to be M-3 and not M-1 as appear in the above smears.