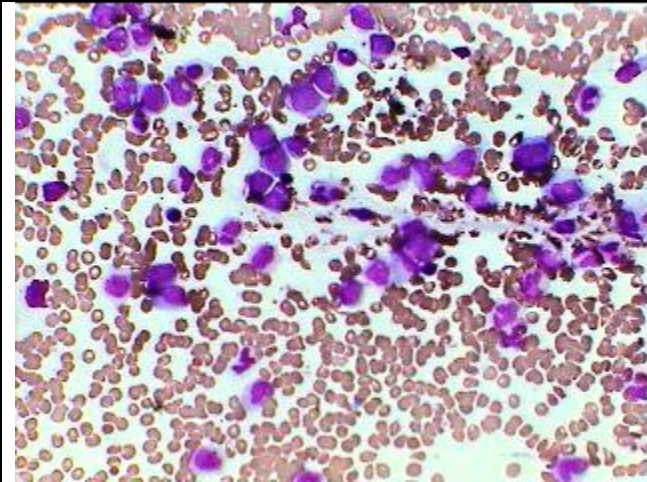




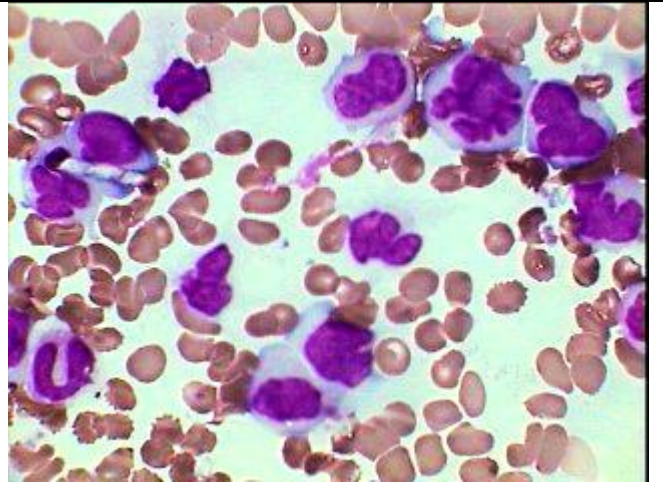
Estd. 1999

www.pathoindia.com

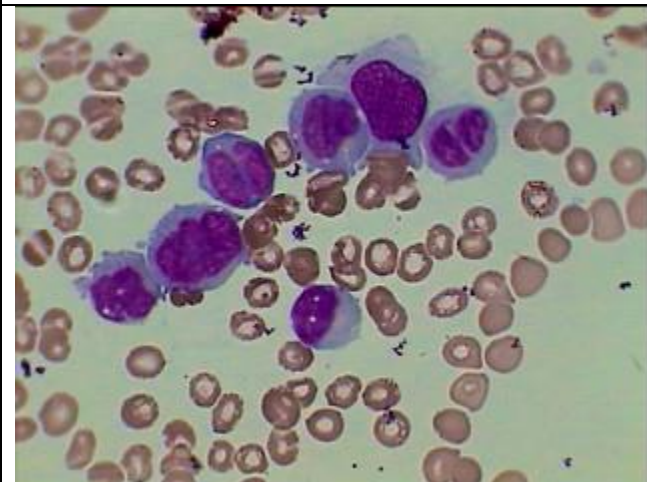
Acute Undifferentiated Leukemia (AUL) Possibility of M-5 could not be ruled out



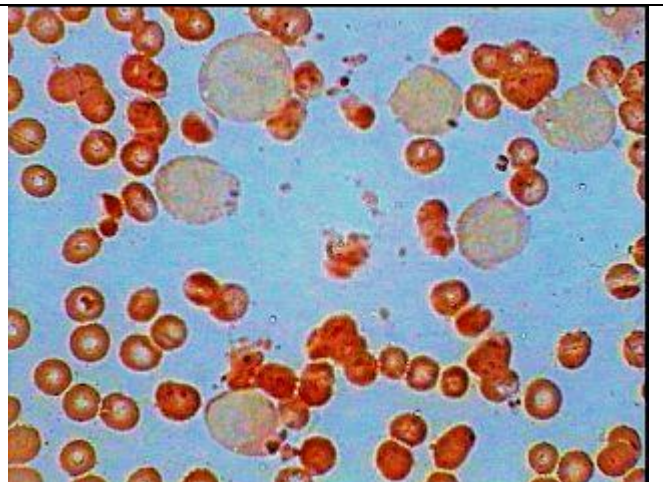
Acute leukemia with thrombocytopenia as seen under HP



Same as on the left showing highly dysplastic ;leucoblasts with voluminous cytoplasm and lobulated nuclei under oil immersion.



Another field of the same patient more regularly shaped large blasts having variable amount of nongranular basophilic cytoplasm



All the blasts cells are peroxidase negative (MPO stain counter stained by safranin)