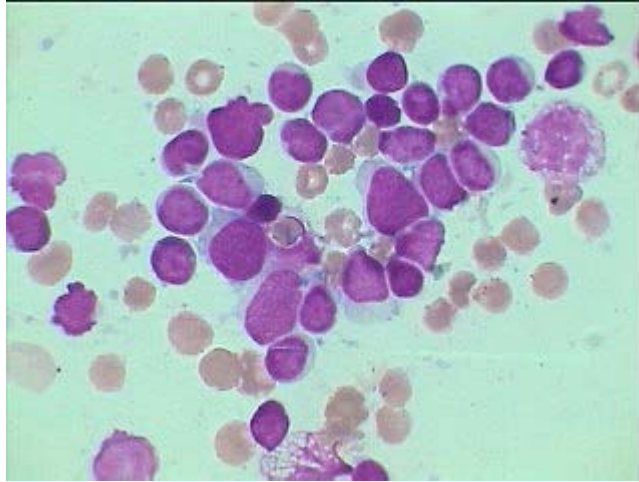
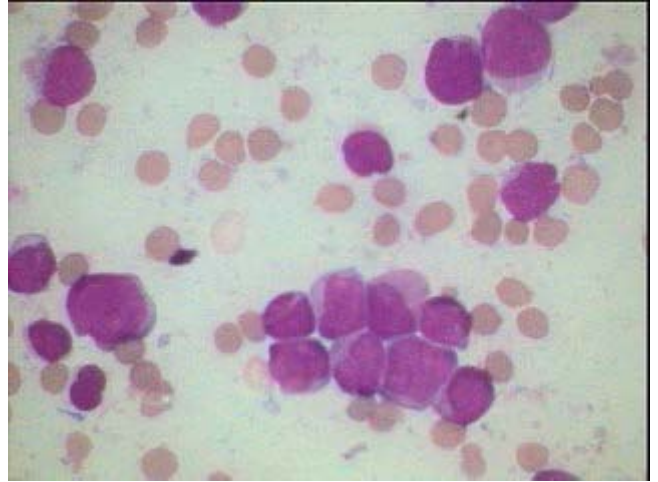


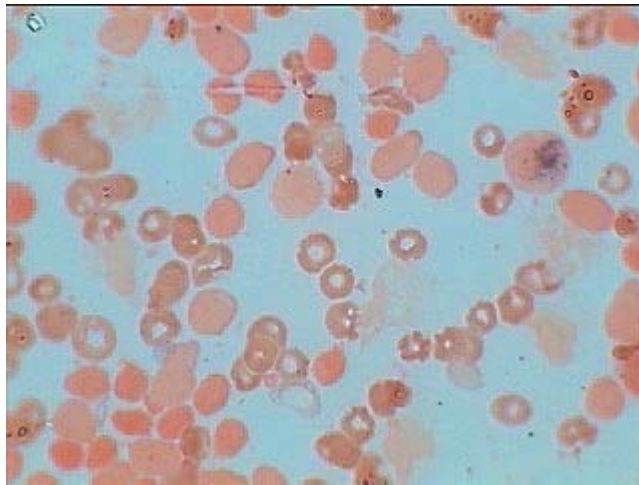
Acute Myeloid Leukemia Type M-0



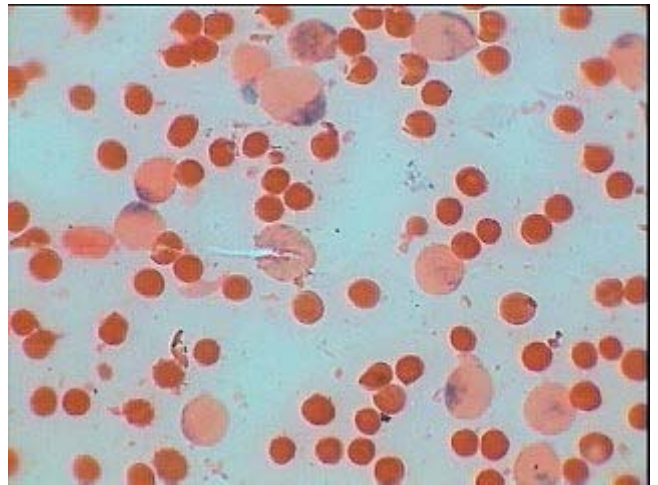
Some relatively smaller and others larger Leucoblasts with scanty cytoplasm having indistinct nucleoli. See MPO stain down below



All relatively larger leukoblasts with moderate pleomorphism some showing distinct nucleoli and morphologically appear Myeloblasts



All the blast cells are MPO Negative except one blasts (upper right) and another showing single dot (top left) peroxidase positivity (less than 3% blast are MPO positive- in M-0)



This is M-1 showing more than 50% blasts being peroxidase positive – compare this with M-0 on the left. MPO stain counter stained by safranin.