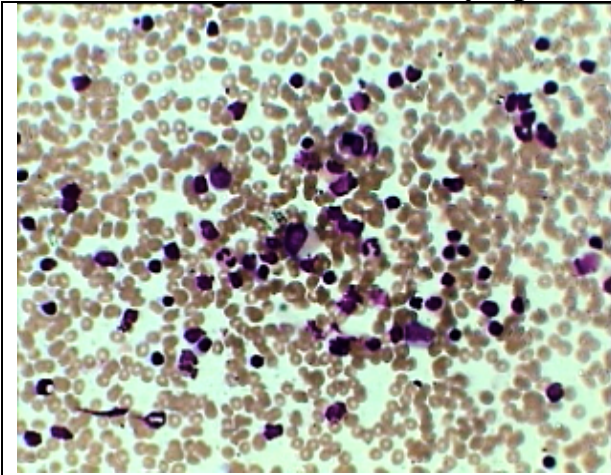
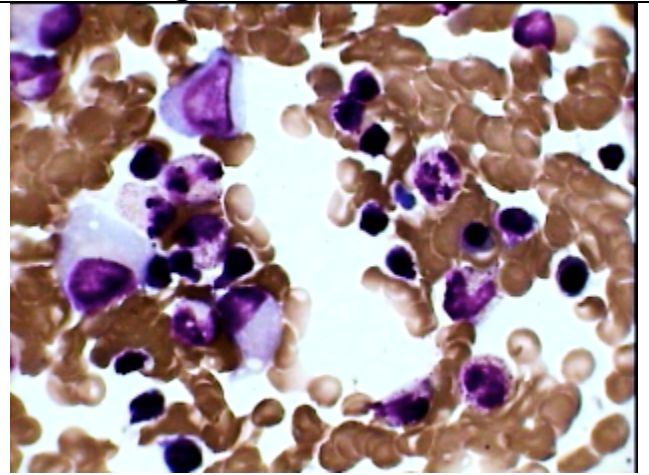




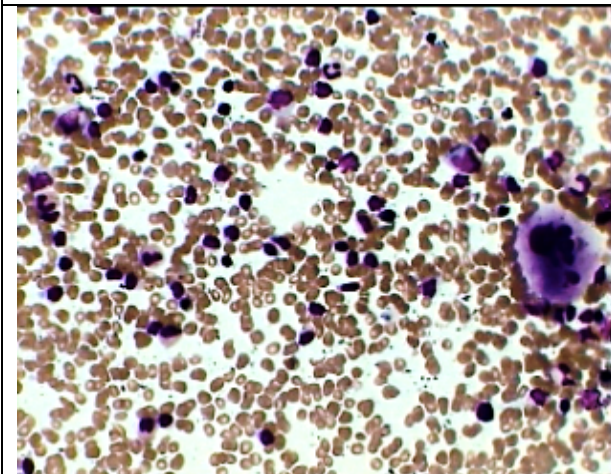
### Small cell Lymphoma Infiltrating the Bone marrow



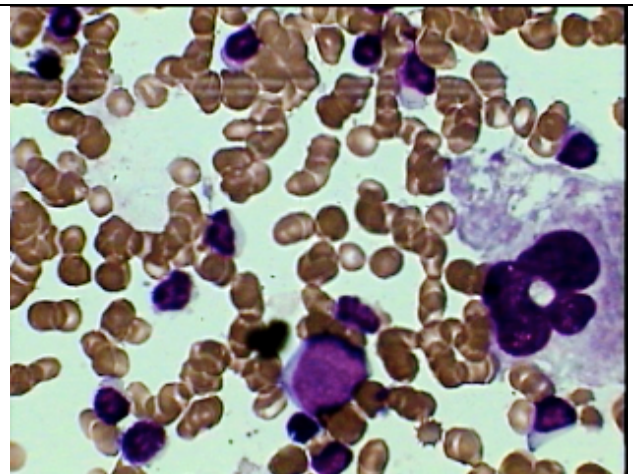
BM smear of Lymphoma infiltration under high power magnification (both diffuse and focal infiltration)



Same smear as on the left under oil Imm. Showing more than 50% lymphoid cells along with with other normal haemopoetic cells



BM Aspiration smear showing one megakaryocyte and good no. of lymphoid cells along with other haemopoetic cells .



Oil Imm view of the same case as on the left emphasizing the uniform small cells, like mature lymphocytes and one parent myeloid cell suggesting small cell lymphoma infiltration.

This 38 year old patient having generalized lymphadenopathy predominantly cervical on histopath exam of biopsy showing NHL . **He has almost normal WBC and differential count with mild anemia.** His BM was done to stage the disease.