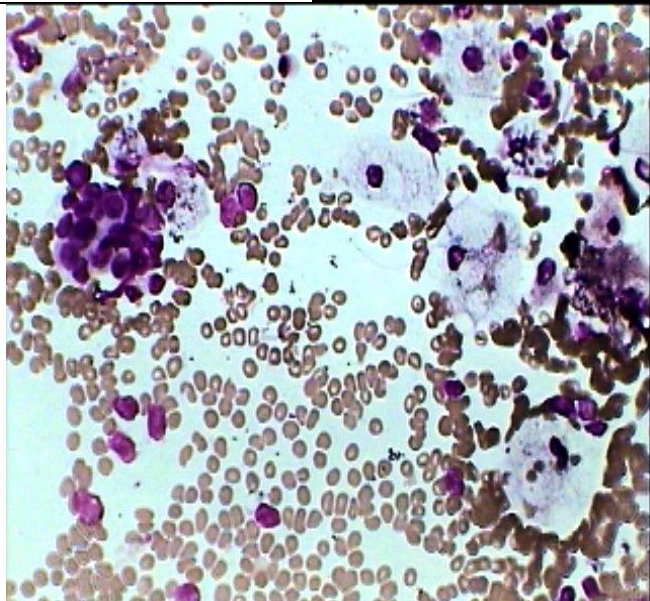
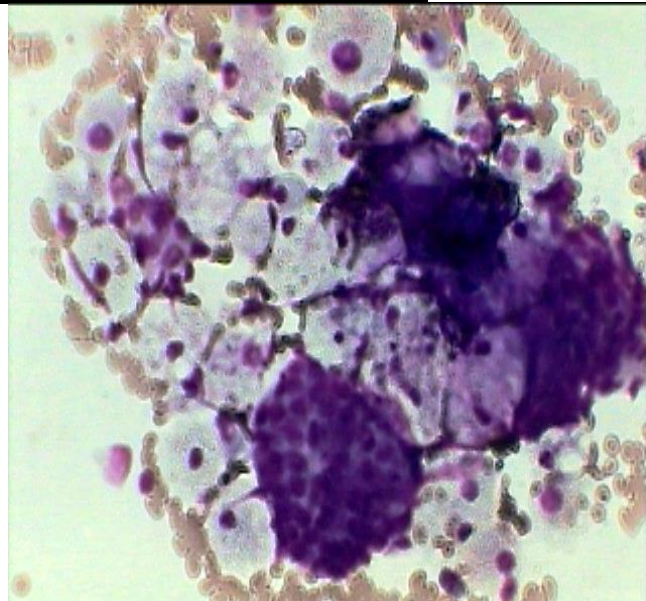


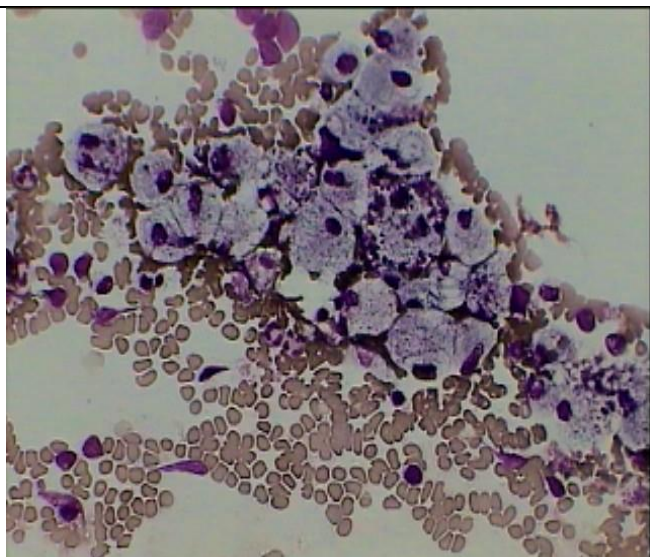
Secondries in the BM asp. Smear with reactive Histiocytes



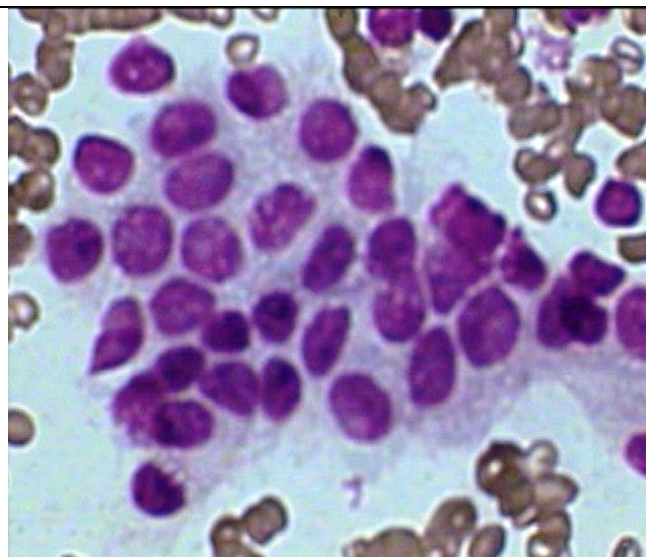
BM Asp Smear showing one compact group of Cells on the left & cells having large foamy cytoplasm with single small nuclei on the right



Another field of the same smear showing single compact group of Non-Haemopoetic cells at the bottom and large reactive histiocytic cells above



This focus shows:-Large number of Reactive histiocytic cells having foamy cytoplasm and small single eccentric nucleus



Another Focus showing -Non-Haemopoetic Neoplastic cells in the BM asp.smear-.under OIm- indicating-Infiltration by Secondries

This 63 yrs old male was referred for BM aspiration/Biopsy but till that time site of primary was not found.