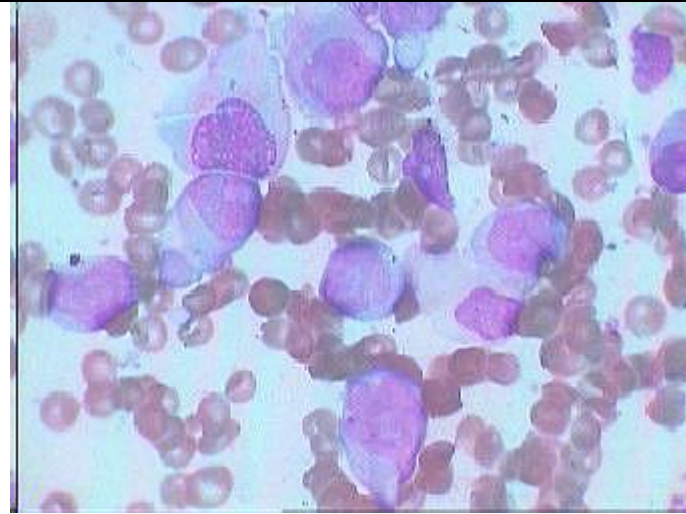
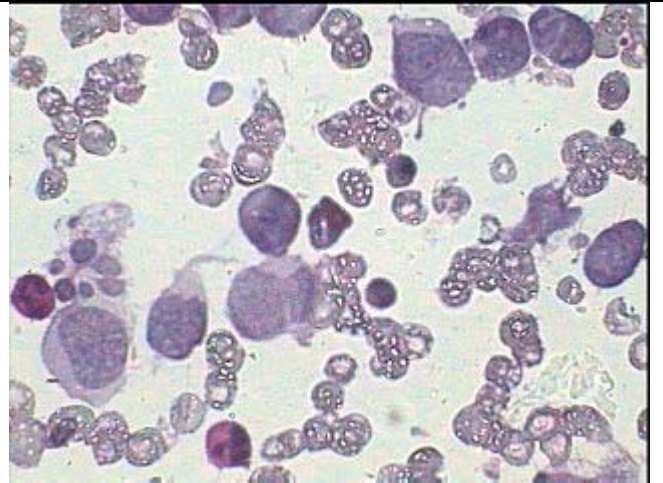


Acute Undifferentiated Leukemia (AUL)

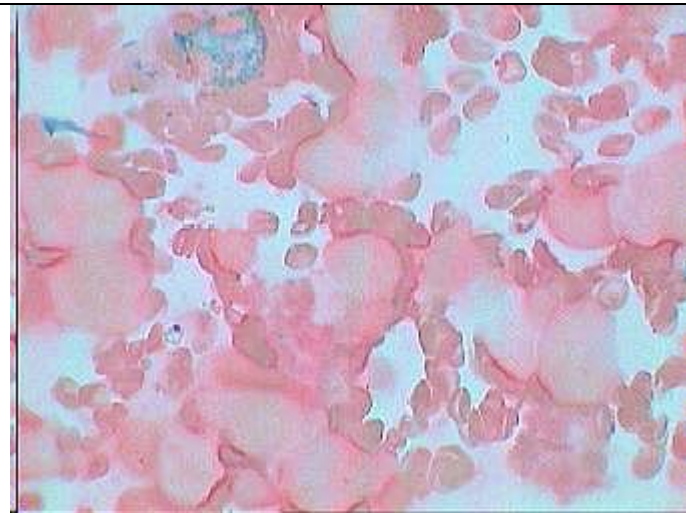
This is presented because of highly Pleomorphic large Leukoblasts in a boy of 9 years



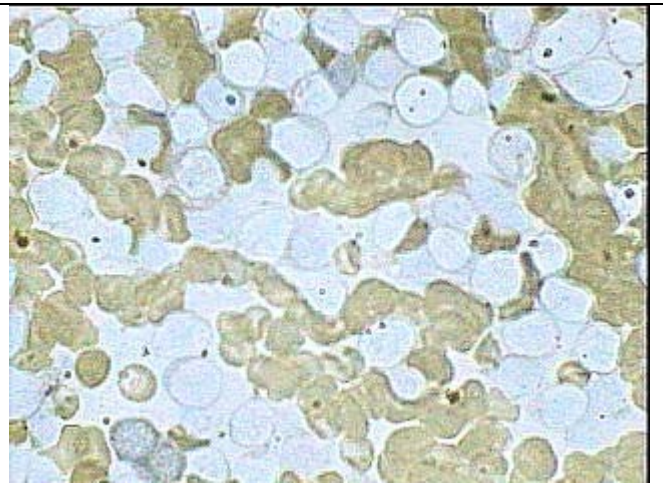
BM Asp. Smear of AUL showing large leucoblasts having voluminous light basophilic cytoplasm and fine nuclear chromatin pattern.



PAS stain showing dot PAS negativity of the blast cells while showing weak diffuse positive mature myeloid cells as control



Same case with MPO stain showing all the blasts are peroxidase negative except one mature myeloid cell at the top



Same case NSE stain showing Non Specific Esterase negativity of these large blast cells