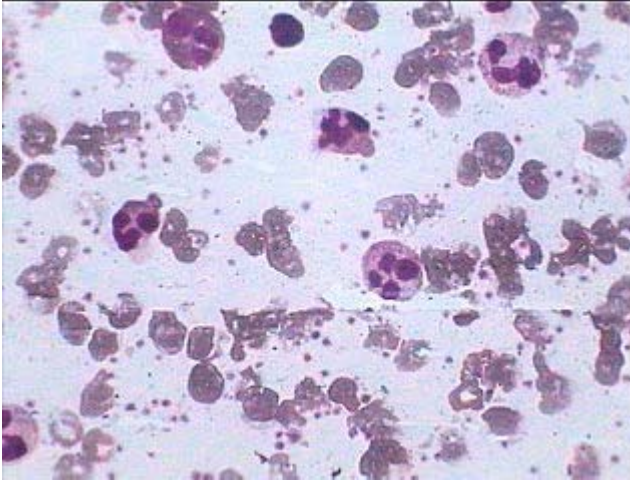
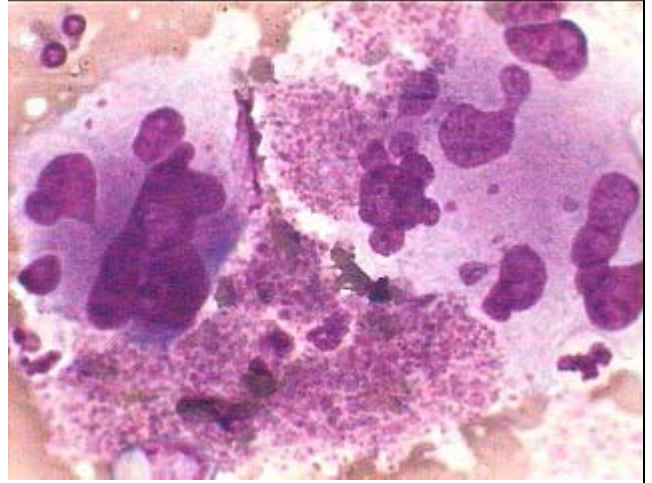


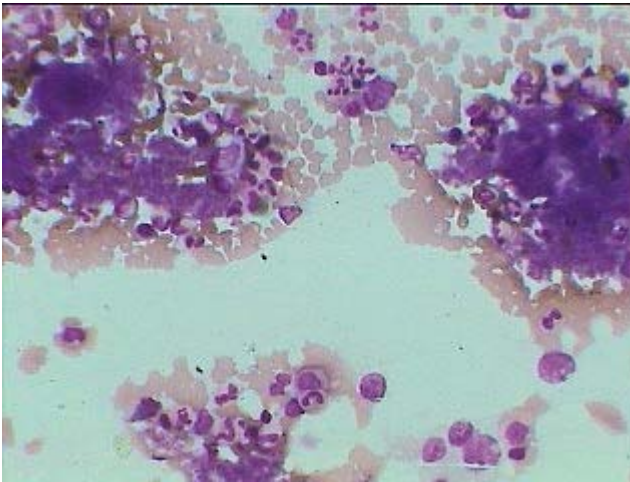
Essential Thrombocythemia (CMPD)



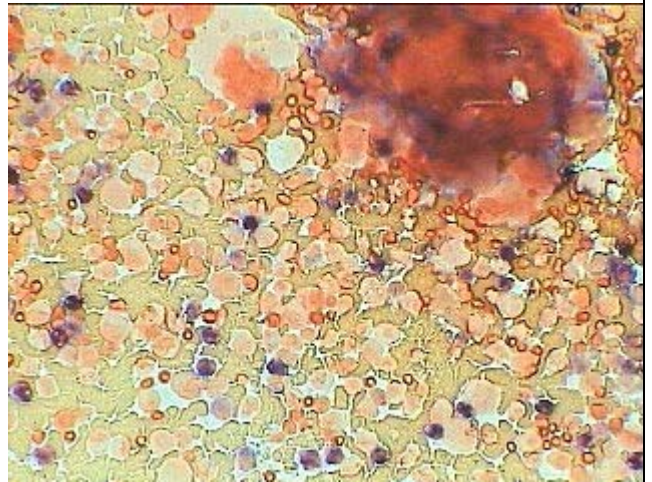
PBF showing Thrombocytosis with increased no. of mature granulocytes



Group of atypical Megakaryocytes with heavy deposit of mature platelets around. Giemsa stain under oil.



Two closely packed group of megakaryocytes surrounded by sheets of platelets along with predominantly mature granulocytes under HP.



High LAP Score as shown by large no. of deep blue stained granulocytes with group of megakaryocytes at upper right corner.