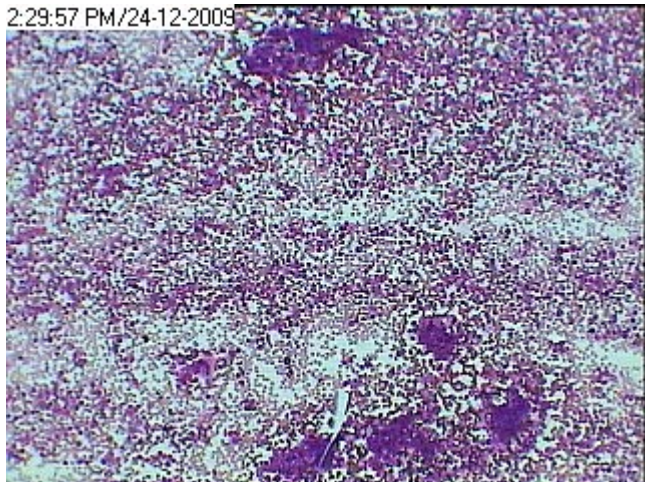


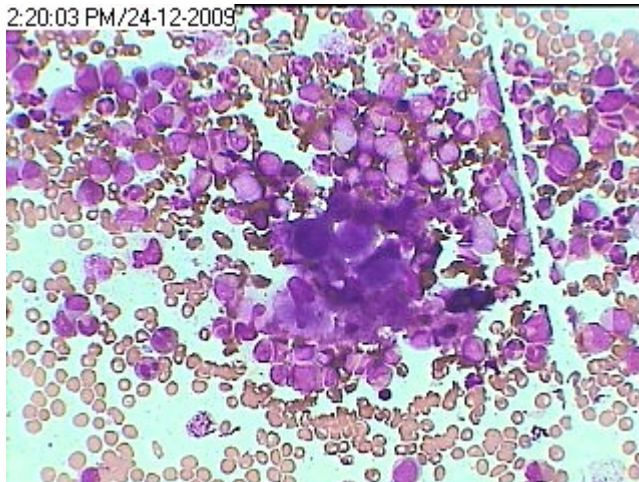
Chr. Myelocytic-Megakaryocytic Leukemia (CGML)

2:29:57 PM/24-12-2009



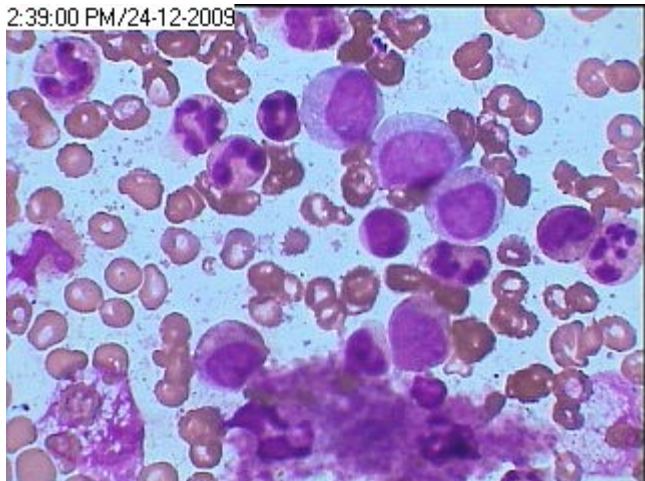LP picture of CGML showing 4 pools of platelets at the bottom and one pool at the top besides hyperplastic myelopoiesis.

2:20:03 PM/24-12-2009



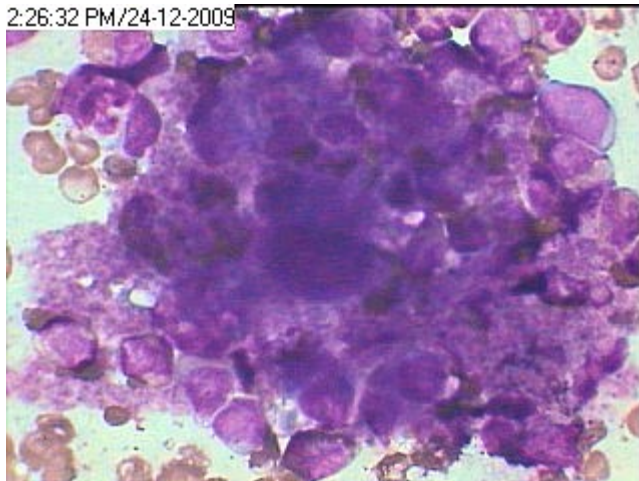
Closely packed group of megakaryocytes with sheet of platelets at the center besides hyperplastic granulopoiesis- HP Image of CGML.

2:39:00 PM/24-12-2009



A pool of platelets at the bottom along with Maturing myeloid cells in CGML

2:26:32 PM/24-12-2009



Markedly hyperplastic Thrombopoiesis (High concentration of mature platelets) packed along with maturing myeloid cells in CGML.