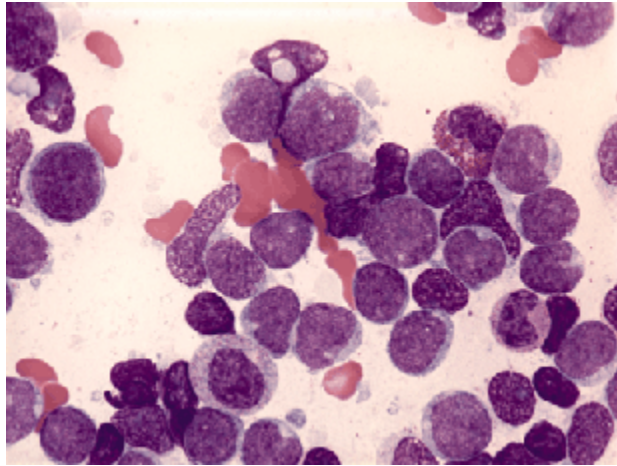
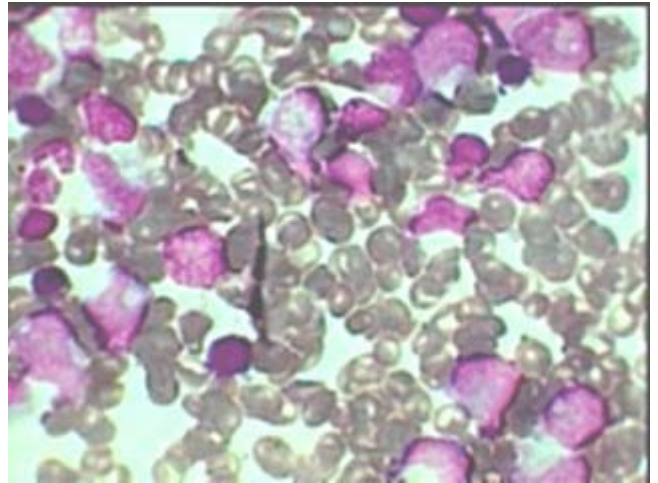


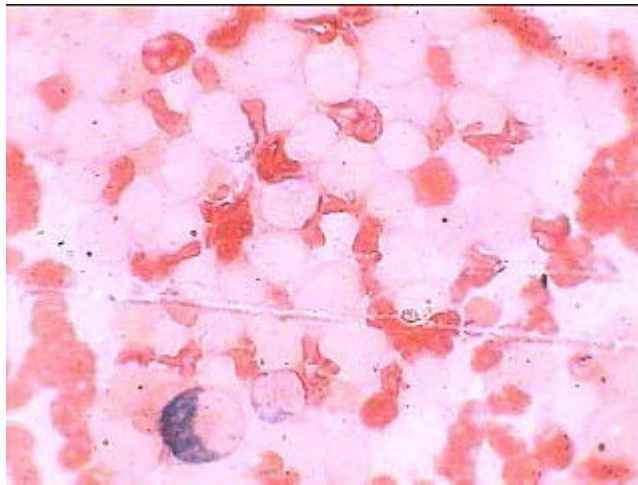Acute Undifferentiated Leukemia



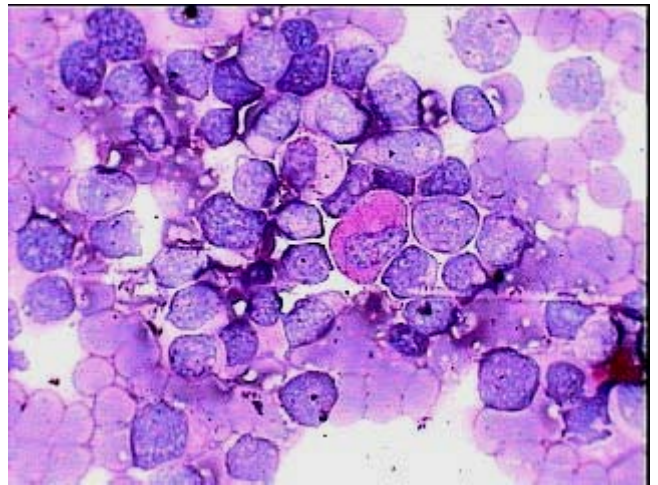
Acute Undifferentiated Leukemia (AUL)-Giemsa stain showing pleomorphic leucoblasts.



Ac. Undifferentiated leukemia (AUL) Lishman stain showing highly atypical leucoblasts



Ac. Undifferentiated leukemia- MPO stain counter stained by Safranin. Only one promyelocyte is positive for peroxidase while all the blasts are negative.



Ac. Undifferentiated Leukemia- PAS stain showing all blasts being negative for dot PAS positivity and only one metamyelocyte showing diffuse positivity.